

AUTHOR QUERY FORM

**LIPPINCOTT
WILLIAMS AND WILKINS**

JOURNAL NAME: BPB

ARTICLE NO: JPOB-07-3641

QUERIES AND / OR REMARKS

QUERY NO.	Details Required	Author's Response
Q1	Per journal style, the length of the abstract should be no longer than 250 words. So, please shorten the abstract.	
Q2	Please note that the structured abstract has been made as a single paragraph (unstructured) as per the journal style.	
Q3	Please check and confirm whether the edits made to Table 1 are appropriate and the table layout is set correct.	
Q4	Per style, the usage of term 'and/or' is not allowed. So, please provide alternate wording for the same in the sentence 'This was easily resolved by guiding the parents to appropriately ...' and elsewhere in the article.	
Q5	Figure 5 are low quality (blurred/unsharp text). Please provide print quality images with minimum 300 dpi resolution, in any of the following formats: TIFF, EPS, MS Word, MS PowerPoint, MS Excel, AI - Adobe Illustrator 10.0, PSD - Adobe PhotoShop 7.0, JPEG, Acrobat PDF.	
Q6	As colour figure(s) are present in your article, there is a \$1000/article charge for them to be produced in colour in the final print and online versions. Please let me know how you wish to proceed.	

Novel device for nonsurgical correction of rigid forefoot adduction in children

Daniel Freedman, Pavel Kotlarsky and Mark Eidelman

Forefoot adduction deformity (FAD) (commonly also called metatarsus adductus) has been reported as the most common congenital foot deformity in newborns. Treatment of FAD depends on the severity of the deformity, and several classification systems have been suggested to categorize the disorder. Early diagnosis and treatment are important in rigid cases, as better outcomes have been reported if treatment is initiated before 9 months of age. While casting and splinting is the current standard of care for nonsurgical management of rigid FAD (RFAD), several orthoses have demonstrated equal benefit. The Universal Neonatal Foot Orthotic (UNFO) brace is below ankle orthosis that provides continuous pressure, thereby correcting the deformity without serial casting. To the best of our knowledge, UNFO is the first brace that operates below the ankle. The aim of our study was to compare the effectiveness of UNFO shoes to standard serial casting in the treatment of RFAD in infants. We performed a retrospective study comparing the efficacy of treatment by casting and splinting to UNFO in infants with RFAD, during the years 2012–2019. Included in the study were 147 feet (94 patients): 52 in the UNFO group and 95 in the casting and splinting group. The treatment groups were compared based on treatment duration, complications, and

recurrence of deformity. Mean full-time treatment duration was significantly shorter in the UNFO group, while no significant difference in the total duration of treatment between the groups was observed. Similar complication rates were demonstrated in both groups; none of the complications in either treatment group warranted treatment cessation or led to long-term disability. Similar recurrence rates were observed in both groups. Treatment with UNFO is equally effective to serial casting. The use of UNFO increases treatment convenience and diminishes social burden, thus providing a distinct advantage over other treatment modalities. *J Pediatr Orthop B XXX: 000–000* Copyright © 2021 The Author(s). Published by Wolters Kluwer Health, Inc.

Journal of Pediatric Orthopaedics B 2021, XXX:000–000

Keywords: foot deformity, forefoot adduction, metatarsus adductus, metatarsus varus, rigid foot deformity

Pediatric Orthopedics, Ruth Rappaport Children's Hospital, Rambam Health Care Campus, Haifa, Israel

Correspondence to Pavel Kotlarsky, MD, Pediatric Orthopedics, Ruth Rappaport Children's Hospital, Rambam Healthcare Campus, 8 Haaliya Hashniya Street, Haifa 3525408, Israel
Tel: +972 50 2061740; e-mail: spavelko@gmail.com

Received 22 January 2021 Accepted 18 April 2021

Introduction

Forefoot adductus deformity (FAD) occurs in one to three cases per 1000 births and has been reported as the most common congenital foot deformity in newborns [1–3]. There is no consensus in the literature regarding the terminology. The most used terms are metatarsus adductus and metatarsus varus. Some use the names metatarsus adductus and metatarsus varus interchangeably to address the same pathology [4]. Others define metatarsus varus as a rigid type of metatarsus adductus [3]. Others although define metatarsus varus as a slightly different deformity where there is supination of the forefoot in addition to forefoot adduction. The deformity is rigid, and a medial deep crease is seen at the transition between the mid and hindfoot [5,6].

FAD is a congenital condition where the forefoot is adducted with respect to the midfoot. Several classification systems have been proposed to help categorize the disorder [2,7–11]. The most popular classification, described by Bleck, uses the heel bisector method, where the severity of the condition is defined by the amount that a line bisecting the heel to the webspace of the second and third toes deviates laterally [7] (Fig. 1). Another frequently used classification system describes the condition based on foot flexibility, classifying the foot as either flexible, semi-rigid, and rigid [8,9,11].

Treatment need for treatment of FAD is controversial and largely depends on its severity: mild and moderate FAD has shown to correct naturally with age [11,12]. However, for rigid FADs (RFAD), prompt evaluation and treatment are essential in managing the condition, as better functional outcomes were reported when treatment was initiated before 9 months of age [6,7,13]. Additionally, remodeling of the tarsometatarsal joint becomes less likely after this time [13,14]. Foot deformities should be corrected prior to the commencement of weight bearing to prevent the negative effects of ground reaction forces

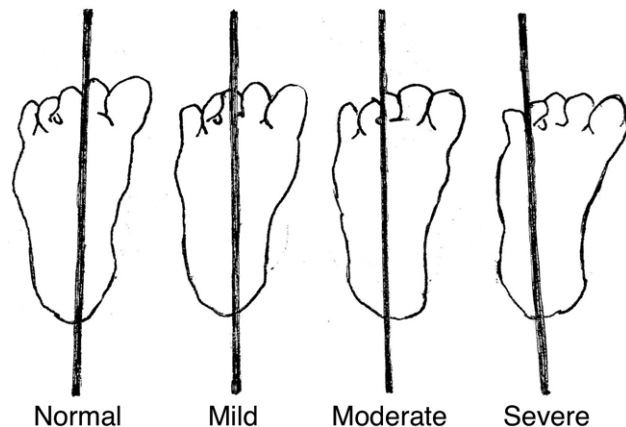
Supplemental Digital Content is available for this article. Direct URL citations appear in the printed text and are provided in the HTML and PDF versions of this article on the journal's website, www.jpo-b.com.

This is an open-access article distributed under the terms of the Creative Commons Attribution-Non Commercial-No Derivatives License 4.0 (CCBY-NC-ND), where it is permissible to download and share the work provided it is properly cited. The work cannot be changed in any way or used commercially without permission from the journal.

on malaligned feet. Left untreated or undertreated, FAD in the older child or young adult can progress to permanent foot deformities, such as hallux valgus [15,16], as well as skewfoot [10]. Furthermore, previous studies have identified a correlation between uncorrected FAD and fifth metatarsal stress fractures [17,18], as well as Jones fractures [19].

The treatment of FAD is mostly nonsurgical, with surgical treatment reserved for treatment-resistant cases in

Fig. 1



Bleck classification method of metatarsus adductus (MA). The normal foot has a line that bisects the heel and the second and third toe web-space. Mild metatarsus adductus has a line that bisects the heel and the third toe, moderate metatarsus adductus has a line that bisects the heel and the third and fourth toe webspace, while severe metatarsus adductus has a line that bisects the heel and the fourth and fifth toe webspace [7].

Fig. 2



The UNFO (Med Ltd.; Holon, Israel) shoes. UNFO, Universal Neonatal Foot Orthotic.

older children [20,21]. Nonsurgical treatment of FAD can be split into orthoses and casting, yet a consensus remains uncertain. Both above knee and below knee casting have demonstrated effectiveness in the treatment of moderate and severe FAD [14,22]. While serial casting has proven efficacious at restoring deformity and currently remains the standard of care, its use is not without complications, thereby highlighting the importance of alternative methods of treatment. Several studies have demonstrated similar results to serial casting using various orthoses and bandages for the treatment of severe FAD, and noted added benefits as well [23,24].

The Universal Neonatal Foot Orthotic (UNFO) shoe (UNFO Med Ltd.; Holon, Israel) is a novel device designed for correction of FAD (Figs 2 and 3). It is composed of polypropylene on the outside and thermoplastic elastomer on the inside, providing constant molding and applying continuous pressure for gradual correction of FAD. To the best of our knowledge, this is the first device that operates below the ankle, mimicking a sandal in design, thus providing much less of a social burden associated with serial casting. To our knowledge, no controlled data exist to date comparing serial casting to below ankle orthoses for the treatment of RFAD.

The aim of our study was to compare the effectiveness of a UNFO shoe to standard serial casting in the treatment of RFAD in infants.

Materials and methods

Research population

This is a retrospective study comparing the efficacy of treatment by casting and splinting to UNFO in infants

Fig. 3



A 3-month-old baby with the UNFO (Med Ltd.; Holon, Israel) shoes on. UNFO, Universal Neonatal Foot Orthotic.

with RFAD. We extracted the data from electronic medical records of all patients who presented to our hospital between 2012 and 2019 with the diagnosis of FAD. The extracted data included: age, sex, type and length of treatment, any complications, and recurrences. During the years 2012–2017, we treated all RFAD patients with casting and splinting protocol. From the beginning of 2018, we switched our treatment to UNFO. We, therefore, compared two retrospective cohorts – casting and splinting treatment (2012–2017) to UNFO treatment (2018–2019).

Inclusion criteria were patients with severe rigid FAD, as defined by the Bleck and the flexibility classification methods, who first presented to our department at less than 1 year of age. Exclusion criteria were patients who had other concurrent medical comorbidities (patients with developmental dysplasia of the hip that were treated and reached Graf type I hip before the commencement of FAD treatment were included) and patients that did not complete the full follow-up period up to walking age. The study was approved by the institutional ethics committee.

Classification:

FAD is primarily classified by two methods. The Bleck classification method describes the deformity by the degree of lateral deviation of a line that bisects the heel and the second and third toe webspace [7]. Description of deformity is outlined in Fig. 1. The other common classification method defines the deformity by the flexibility of the foot under passive manipulation. One that easily returns to midline is considered flexible, one that partially returns to midline is considered semi-rigid, and a foot unable to be returned to midline is considered rigid [8,9,11,13]. When in addition to forefoot adduction, forefoot supination is present, a deep medial crease at the transition between the mid and hindfoot is present [5,6].

Universal Neonatal Foot Orthotic treatment protocol

The UNFO shoes have two sizes and are designed to fit patients between ages 2 and 12 months (Figs 2

and 3). The smaller size intended for feet 7–9 cm in length, and the bigger size for feet 9–10 cm in length. Treatment ideally should commence between 3 and 6 months of age. During the first 6 weeks, the patients were treated full time, for 23 h daily, allowing a brief removal of the shoe twice daily for hygienic purposes. After 2 weeks of treatment, we expect to achieve near correction. Following additional 4 weeks, a slight over-correction is expected. At this stage, the parents were instructed to start maintenance protocol for the following 6 weeks: 3 weeks of 15 h/day, and the rest 12 h/day (Fig. 4). If a patient had a recurrence of deformity during the maintenance period, additional 2 weeks of full-time treatment was administered, with a subsequent similar 6-week tapering period. Routine follow-ups were scheduled 1 month following treatment cessation, and then several follow-ups until the commencement of ambulation.

F4

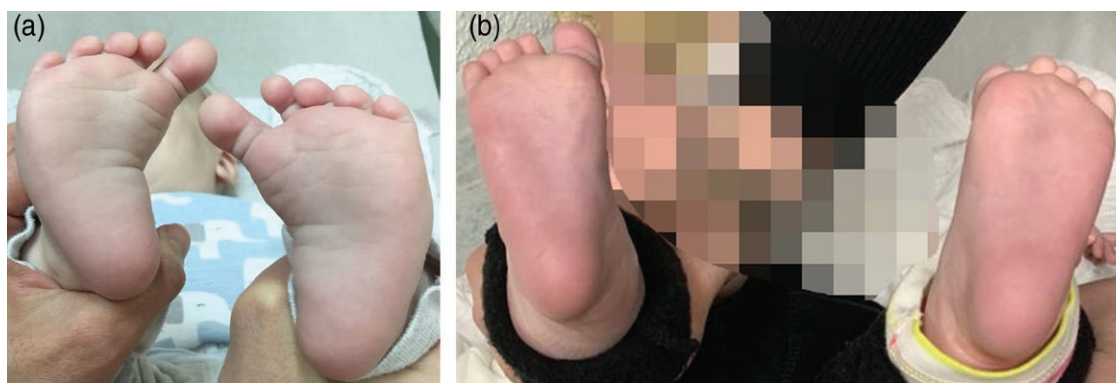Casting and Splinting treatment protocol

Patients were placed in an above-knee cast for 2 weeks. After this period, if the correction was not achieved, they were cast for two additional weeks. Subsequently, the patients were placed in a custom-made ankle-and-foot-orthosis (AFO) for maintenance of correction for 8–16 weeks: the first half in a full-time splint (23 h/day) and the second half in a part-time splint (12 h/day).

Data analysis

We compared the treatment methods based on the duration of treatment (full-time vs. part-time), associated complications, and recurrence of deformity. In the casting and splinting group, full-time treatment was length of time the patient was in a cast combined with the time in a full-time splint. In the UNFO group, full-time treatment was defined as the period in which the patient was instructed to wear the shoe for 23 h daily. Recurrence of FAD was defined as any feet that required treatment after being deemed corrected.

Fig 4



. Four and a half months old patient with bilateral rigid forefoot adduction deformity (RFAD); (a) initial deformity before treatment, (b) the result one month after cessation of treatment.

AQ3

Table 1 Demographics of patients receiving Universal Neonatal Foot Orthotic and casting and splinting treatments

Treatment group	Average age at presentation (months \pm SD ^a)	Number of feet	Left feet ^b	Right feet ^b	Male	Female
UNFO	5.45 \pm 2.09	52	27	25	32	20
Casting and splinting ^c	4.23 \pm 1.94	95	51	44	57	38

The difference in the average age at first presentation was statistically significant with $P < 0.01$.

UNFO, Universal Neonatal Foot Orthotic.

^aSD.

^bL – left, R – right.

^cCasting and splinting group.

Statistical analysis

Descriptive statistics were used to describe and analyze the data relating to patient characteristics, recurrence, and complication rates. A two-tailed *t*-test with a *P* value < 0.05 for significance was used to compare the two treatment populations for age of the first presentation and for comparison of treatment duration.

Results

Between the years 2012 and 2019, 174 feet (111 patients) with RFAD presented to our department. Out of these, 27 feet in the casting and splinting group were lost to follow-up and were excluded. Included in the final analysis were 147 feet (94 patients): 52 in the UNFO group and 95 in the casting and splinting group. Patient demographics are described in Table 1.

T1

F5

The length of treatment is depicted in Fig. 5. Although full-time treatment was shorter in the UNFO group by approximately 1 week, there was no significant difference in total treatment duration.

The complication rates were 0.17 and 0.13 in the UNFO and casting and splinting groups, respectively. In the UNFO group, mild skin irritation was noted in three feet, and superficial pressure sores in four feet. In the casting and splinting group, skin abrasions secondary to cast removal was seen in four feet, and superficial pressure

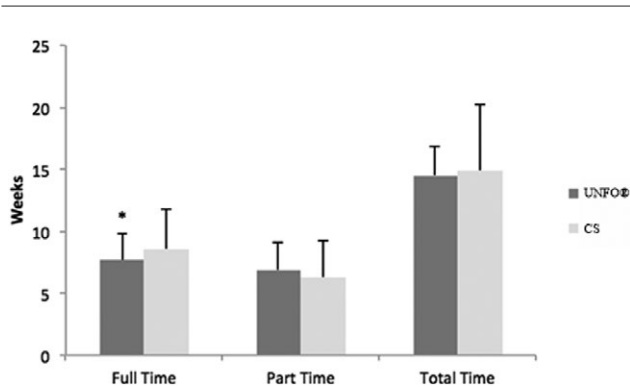
sores in seven feet. None of the complications in either treatment group warranted treatment cessation or led to long-term disability.

The recurrence rates were 0.05 and 0.06 in the UNFO and casting and splinting groups, respectively. In the UNFO group, a recurrence was noted in two feet of one patient at the age of 7 months. This patient's parents initially placed the UNFO on the wrong feet, thereby, exacerbating the deformity. This mistake was realized and explained to the parents at the first 2 weeks of follow-up, whereby treatment was subsequently restarted. The patient reached correction after 6 weeks of full-time treatment, but recurrence was noted 3 weeks into part-time treatment. The protocol was restarted from the beginning, and eventually, full correction was achieved. In the casting and splinting group, five feet of three patients had a recurrence of deformity at a mean age of 13.4 months, which necessitated reinitiating full-time treatment (without casting).

Discussion

Forefoot adduction deformity (FAD) is the most common congenital foot deformity^{1,2}. While mild and moderate deformities can resolve spontaneously; severe deformity, especially when of the rigid type, and combined adduction and supination type deformity requires

Fig. 5



Comparison of treatment duration between UNFO and casting and splinting groups. The difference in the length of full-time treatment was statistically different with $P=0.01$. Statistical significance is indicated by *. The error bars represent one SD. UNFO, Universal Neonatal Foot Orthotic.

treatment [6,13]. When indicated, treatment should commence as soon as possible, preferably before 9 months of age [7]. The current standard treatment is serial casting to achieve correction followed by a splint to maintain the achieved correction. To the best of our knowledge, the UNFO (UNFO Med Ltd.; Holon, Israel) shoe is the first device that operates below the ankle mimicking a sandal in design. To our knowledge, this is the first study directly comparing serial casting to below ankle orthoses in the treatment of RFAD.

In our study population, comparable proportions of sex and foot laterality were observed between the two patient groups, demonstrating the similarity of the two investigated populations. We observed that in the casting and splinting group, the treatment was initiated roughly one month earlier than in the UNFO group. This is because there is no time restriction to commencement of casting and splinting treatment whereas the UNFO is only designed for infants between 2 and 12 months. Despite the later onset of treatment in the UNFO group, we failed to observe any difference in the final result or recurrence rate. This fact is supported by the literature; as long as treatment is initiated before 9 months of age, better outcomes are expected [7,25].

No significant difference in the total duration of treatment between the groups was observed. However, the mean full-time treatment duration was significantly shorter in the UNFO group. In both groups, few patients required longer treatment. The two main reasons were the presence of deep medial crease at the transition between the mid and hindfoot as well as poor parental treatment compliance. Based on our experience, we recommend modifying the UNFO protocol in patients with deep medial crease, by continuing full-time treatment for a period of 8 weeks instead of six. The subsequent maintenance period should remain the same.

There was a very low and comparable rate of minor skin complications in both groups, though, none warranted cessation or modification of treatment, or resulted in any long-term disability. In the UNFO group, superficial pressure sores were seen over the pressure points of the shoe on the heel and the first metatarsal head. The UNFO shoes can be easily modified to relieve pressure from these areas (Video 1, Supplemental digital content 1, <http://links.lww.com/JPOB/A58> describes the technique for shoe modification). After implementing this shoe modification technique, no further complications were observed. Additionally, parents are advised to dress their infants in thicker socks and to use the dedicated hygiene periods during full-time treatment to prevent and monitor for superficial skin complications. In a few patients, the parents complained that the shoe occasionally came off. This was easily resolved by guiding the parents to appropriately tighten the hook and loop strap and/or reinforce the grip around the foot using a paper tape. The modifiability of the UNFO, as well as the assigned period for daily foot inspection, offer it a distinct advantage allowing for earlier detection and treatment of complications.

Similar recurrence rates were observed in both groups. The recurrence in the UNFO group occurred in both feet of a single patient that were related to poor parental compliance throughout all stages of treatment, as previously described. This case stresses the importance of ensuring parental understanding and commitment before the commencement of treatment, particularly, when using removable orthotics that give parents full control over the treatment.

While all patients in our study achieved full correction of the deformity, with none requiring surgery, several advantages for orthoses over casting and splinting treatment have been previously demonstrated. In a randomized controlled trial comparing the use of Bebox orthoses to serial casting, equal effectiveness was demonstrated between the two methods in the treatment of severe metatarsus adductus in patients younger than 9 months of age [23]. Other benefits for the use of orthoses have been identified, including lower cost and better hygiene [23,25]. Additional burdensome factors associated with casting include the potential for serious complications such as circulatory and nerve problems if the cast is applied too tight [11], and the associated difficulty in identifying complications, other than toe discoloration, while in full-time casting [25]. Additionally, in implementing the UNFO protocol, we reduced both the length and number of treatment visits, compared to the casting and splinting protocol. Cosmetically, UNFO looks like a sandal, which led to higher parental satisfaction with the treatment. Furthermore, only one shoe is needed throughout the whole treatment, without any adjustments or modifications (except for a replacement of the hook and loop strap which got worn-off during treatment in a small number

of cases). These factors help illuminate the superiority of orthoses in comparison to serial casting.

For many years, serial casting with subsequent AFO splint was the standard treatment protocol in our institution. However, following the appearance of the UNFO shoes, we found the UNFO protocol to be far more convenient and equally effective. Moreover, the patients' parents' satisfaction was also remarkably high with the UNFO treatment, as well as the cost was slightly lower, compared to casting and splinting protocol. Consequently, starting from 2018 we have treated all our FAD patients with UNFO.

Conclusion

The results of our study indicate that the treatment with UNFO is equally effective to serial casting, the current standard of care. All infants with RFAD treated with UNFO achieved timely full correction without any major complications. The use of UNFO increases treatment convenience and diminishes social burden, thus providing a distinct advantage over other treatment modalities.

Acknowledgements

Conflicts of interest

There are no conflicts of interest.

References

- Dietz FR. Intoeing – fact, fiction and opinion. *Am Fam Physician* 1994; **50**:1249–1259,1262–1264.
- Karami M, Ebrahimpour A, Aminizadeh Y, Moshiri F, Karimi A, Radyn Majd A. Foot scan assessment of metatarsus adductus: a useful adjunct to Bleck's classification. *Foot (Edinb)* 2018; **34**:74–77.
- Staheli LT. Foot. In: Staheli L, ed. *Fundamentals of Pediatric Orthopedics*. 5th ed. Philadelphia: Lippincott Williams & Wilkins; 2014:166–168.
- Metatarsus Adductus. <https://www.chop.edu/conditions-diseases/metatarsus-adductus>. Accessed August 9, 2020.
- Kane R. Metatarsus varus. *Bull N Y Acad Med* 1987; **63**:828–834.
- Visser JD. *Pediatric Orthopedics*. Cham: Springer International Publishing; 2017.
- Bleck EE. Metatarsus adductus: classification and relationship to outcomes of treatment. *J Pediatr Orthop* 1983; **3**:2–9.
- Rerucha CM, Dickison C, Baird DC. Lower extremity abnormalities in children. *Am Fam Physician* 2017; **96**:226–233.
- Connors JF, Wernick E, Lowy LJ, Falcone J, Volpe RG. Guidelines for evaluation and management of five common podopediatric conditions. *J Am Podiatr Med Assoc* 1998; **88**:206–222.
- Wan SC. Metatarsus adductus and skewfoot deformity. *Clin Podiatr Med Surg* 2006; **23**:23–40, vii.
- Williams CM, James AM, Tran T. Metatarsus adductus: development of a non-surgical treatment pathway. *J Paediatr Child Health* 2013; **49**:E428–E433.
- Eamsobhana P, Rojjananukulpong K, Ariyawatkul T, Chotigavanichaya C, Kaewpornasawan K. Does the parental stretching programs improve metatarsus adductus in newborns? *J Orthop Surg (Hong Kong)* 2017; **25**:2309499017690320.
- Mosca VS. Foot and Ankle Deformities. In: Mosca VS, ed. *Principles and Management of Pediatric Foot and Ankle Deformities and Malformations*. 1st ed. Philadelphia: Wolters Kluwer Health; 2014:94–96.
- Bohne W. Metatarsus adductus. *Bull N Y Acad Med* 1987; **63**:835–838.
- Banks AS, Hsu YS, Mariash S, Zirm R. Juvenile hallux abducto valgus association with metatarsus adductus. *J Am Podiatr Med Assoc* 1994; **84**:219–224.
- Ferrari J, Malone-Lee J. A radiographic study of the relationship between metatarsus adductus and hallux valgus. *J Foot Ankle Surg* 2003; **42**:9–14.
- Wamelink KE, Marcoux JT, Walrath SM. Rare proximal diaphyseal stress fractures of the fifth metatarsal associated with metatarsus adductus. *J Foot Ankle Surg* 2016; **55**:788–793.
- Theodorou DJ, Theodorou SJ, Boutin RD, Chung C, Fliszar E, Kakitsubata Y, Resnick D. Stress fractures of the lateral metatarsal bones in metatarsus adductus foot deformity: a previously unrecognized association. *Skeletal Radiol* 1999; **28**:679–684.
- Yoho RM, Carrington S, Dix B, Vardaxis V. The association of metatarsus adductus to the proximal fifth metatarsal Jones fracture. *J Foot Ankle Surg* 2012; **51**:739–742.
- Knörr J, Soldado F, Pham TT, Torres A, Cahuzac JP, de Gauzy JS. Percutaneous correction of persistent severe metatarsus adductus in children. *J Pediatr Orthop* 2014; **34**:447–452.
- Feng L, Sussman M. Combined medial cuneiform osteotomy and multiple metatarsal osteotomies for correction of persistent metatarsus adductus in children. *J Pediatr Orthop* 2016; **36**:730–735.
- Katz K, David R, Soudry M. Below-knee plaster cast for the treatment of metatarsus adductus. *J Pediatr Orthop* 1999; **19**:49–50.
- Herzenberg JE, Burghardt RD. Resistant metatarsus adductus: prospective randomized trial of casting versus orthosis. *J Orthop Sci* 2014; **19**:250–256.
- Utrilla-Rodríguez E, Guerrero-Martínez-Cañavete MJ, Albornoz-Cabello M, Munuera-Martínez PV. Corrective bandage for conservative treatment of metatarsus adductus: retrospective study. *Phys Ther* 2016; **96**:46–52.
- Chong A. A new device for the treatment of metatarsus adductus. *J Prosthetics Orthot* 1990; **2**:139–148.